

# Evaluation of Collagen, Calcium Alginate Protectants on Healing of External Wound on Teat in Cows

N. Arul Jothi\* and T.P. Balagopalan

Department of Veterinary Surgery and Radiology, Teaching Veterinary Clinical Campus, Rajiv Gandhi Institute of Veterinary Education and Research, Pondicherry, 605009, India

**Abstract:** A total number of 36 cross bred jersey cows with external teat injury without involving the teat cistern and with exposed teat sinus were subjected for the present study. Clinical examination of teat for its shape, length, distance from the ground and etiology of the teat wounds were recorded. Following preoperative evaluation, the animals were divided into Group I with 12 animals and treatment group with 24 animals each. Group I were treated with Povidone iodine solution. In treatment (Group II), after suturing the wound was protected with sheets of collagen and calcium alginate as protectants. The application of collagen based teat protectant is an effective methodology for favoring healing process of external injuries when compared to the conventional antiseptic drugs using Povidone iodine.

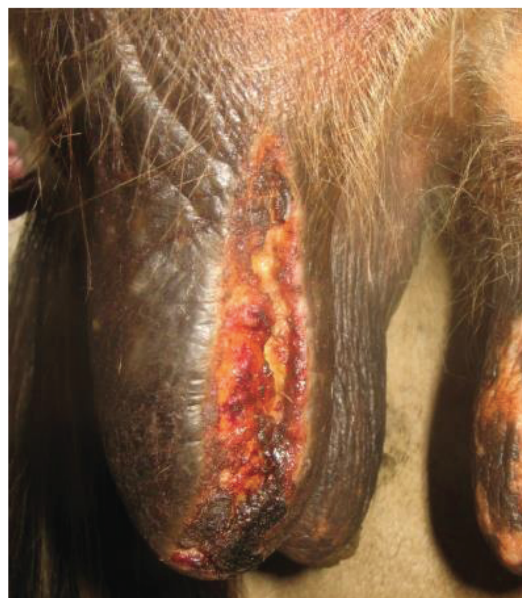**Keywords:** Biomaterial, Teat Protectant, Teat wound, Teat fistula, Ultrasound scanning.

## INTRODUCTION

Teat injuries are common in dairy cattle, and, compared with other frequently occurring diseases, these injuries often result in premature culling of affected cows. Teat injury can be full thickness exposing teat cistern or partial thickness [1]. The sensitive nature of the tissue, quick and extensive inflammatory responses cause pain while milking and lead to mastitis. External injury like lacerations without involving teat cistern can be treated successfully. Deeper wounds of the teats should be cleansed and sutured under local anesthesia with appropriate sedation and restraint, but the affected quarters are prone for infection, and prophylactic treatment is necessary to prevent mastitis. Nichols (2008) [2] divided teat injuries into two categories as external and internal. Nouh *et al.* (2014) [3] classified the teat injuries to superficial and deep injuries. Biomaterials play an important role to enhance early wound healing in teat wounds to prevent pain, mastitis and early culling of the milking cows. Teat protectants were employed to favor early healing, to retain teat lumen patency and to prevent post-treatment complications (REF). Early wound healing can be promoted with collagen + calcium alginate biomaterial [4] to prevent mastitis. In the present study, the effect of a teat protectant made up of bovine collagen and calcium alginate mixture on healing of external wound on teat was evaluated and compared to standard procedure using Povidone iodine.

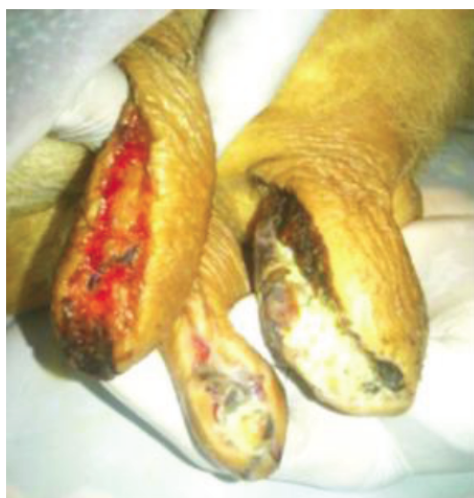## MATERIALS AND METHODS

A total number of 36 cross bred jersey cows with external teat injury without involving the teat cistern (Figure 1) and with exposed of teat sinus (Figure 2) were subjected for the present study. All the cows were cross bred Jersey. Clinical examination of the teat for its, teat shape, length, distance from the ground and etiology of the teat wounds were recorded. Following preoperative evaluation, the animals were divided into control group with 12 animals treated with Povidone iodine and treatment group with 24 animals each. In control (Group I) the external wound was sutured as per the standard procedure and protected with gauze with Povidone iodine solution. In treatment (Group II), after suturing the wound was protected with sheets of collagen and calcium alginate as protectants.



**Figure 1:** external teat wound.

\*Address correspondence to this author at the Department of Veterinary Surgery and Radiology, Teaching Veterinary Clinical Campus, Rajiv Gandhi Institute of Veterinary Education and Research, Pondicherry, 605009, India; Tel: 9442070610; E-mail: vsr\_jo@yahoo.co.in



**Figure 2:** Exposed teat cistern.


Animal particulars, Morphometric details like shape of the udder and teats were recorded.

The age of the animals was between 2.5 to 5.8 years with the body weight ranged from 397 to 428 kg. The age at first calving of the cows was ranged from 2.33 to 2.58 years. Animals presented were between 1st and 4th lactation and all the cows were maintained with calves alive at an age group between 99-228 days. Shape of the teat was cylindrical in 32 (88.89%) animals and funnel in shape in 4 (11.11%). The length of the teat was ranged from 5.15 to 6.36 cm. The distance from floor to teat tip was ranged from 37.16 to 43.53cm. The distribution of the affected teat in the cows was left hind 33% (12), right fore 25% (9) left fore 22% (8) and right hind 20% (7).

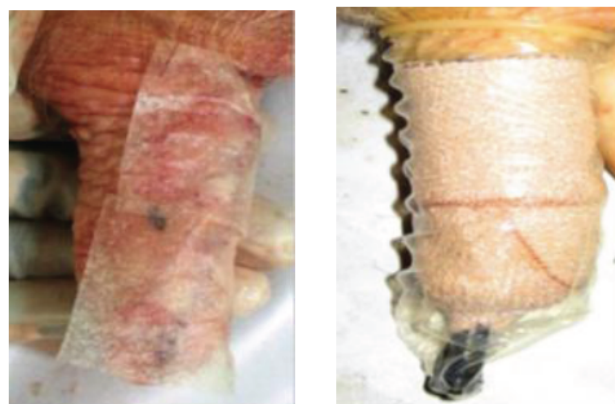Ultrasonographical examination of the affected teat was performed by B-mode diagnostic ultrasound scanner using 7.5 MHZ linear probe by water bath method. The teat was dipped in a thin transparent polyethylene cup filled with water. The transducer was placed in vertical/ horizontal planes on the outer wall of the cup. Nature of lesion and other pathological structural changes if any were documented on day one and 10<sup>th</sup> post treatment day.

Animals with and exposed teat sinus were sedated by administering Inj. Xylazine (Xylaxin-Indian Immunologicals Ltd) at the dose rate of 0.1 mg/kg body weight intravenously. The animal was kept on lateral recumbency with the affected teat placed above. The local analgesia of the teat was achieved by ring block using 2% Lignocaine hydrochloride (Lignocaine 2%-Tamman Titoe Pharma Pvt. Ltd., Tamilnadu). The affected teat was prepared for aseptic surgery. The

wound on the teat was irrigated with 0.5% Povidone Iodine solution (Betadine-Win Medicare) and debrided after inserting a sterile metal teat siphon. Reconstruction of the exposed teat sinus was performed by suturing its edges in simple continuous pattern. Mattress sutures passing through the skin and subcutis on one edge and subcutis on other edge were employed using 3/0 polyglactin 910 (Vicryl Plus – Johnson and Johnson, Mumbai). Postoperatively, the teats were protected with Povidone iodine gauze in biodegradable teat protectants in the form of sheet (3 x 3 cm in size) made up of bovine collagen and calcium alginate mixture manufactured and sterilized with Gamma radiation (Figure 3) in control and treatment groups respectively. The teat applied with protectants were kept in position by adhesives and protected from contamination by applying a sterile condom over the entire teat (Figure 4). Milk from the quarter was drained daily and infused the teat cistern with intramammary infusion containing Metronidazole and Povidone Iodine. Inj. Streptopenicillin @ 10mg/ kg body weight was administered intramuscularly daily for 5 days in all the animals. The wound dressing was done on 5<sup>th</sup> postoperative day in all the animals.



**Figure 3:** Collagen + calcium alginate teat protectants (3 x 3 cm sheet).



**Figure 4:** Suture site applied with Protectant and Bandaged.

## RESULTS AND DISCUSSION

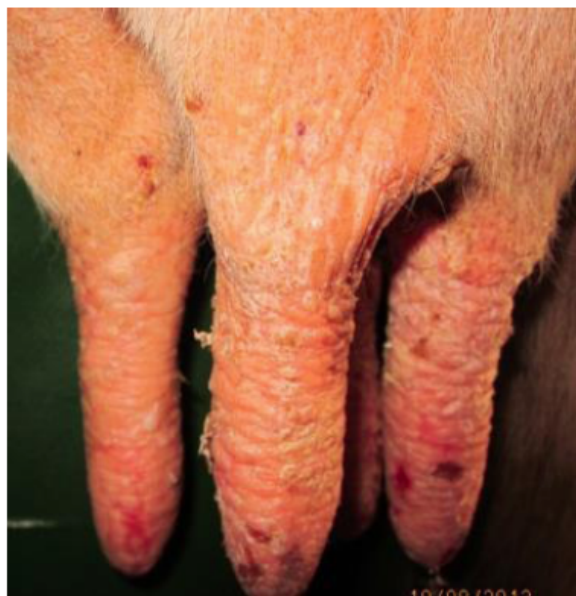Major etiology reported was injury due to barbed wire (13) followed by hot water and unknown etiology (4 each), Sharp objects, broken glass, thorns, knuckling (3each), Dryness (2) and crush injury (1). Aruljothi *et al.* (2012) [5] also reported that the common etiological factor for external wound on teat were barbed wires, thorns, broken glass, sharp objects, dog bite and hot water.

The type of wounds were classified into lacerated wound 31% (11), Incised wound 19% (7), Avulsion (14%) and teat crack (14%) (5 each). Scald 11% and wound with myiasis 11% (4 each). Wounds were observed throughout the length of teat in 13 cases (36%), at the base in 5 (14%) and at mid teat (25%) and tip (25 %) in 9 cases each in the study.

On day 5, the animals in control group showed pain on palpation of the teat, difficulty in milking and wound with healing tendency. In the treatment group, the collagen + calcium alginate sheet were found to be well accepted by the animals got absorbed by 5th day of application without any reaction, slight pain was noticed on palpation of the teat with difficulty in milking.

On 10th day postoperatively, control group did not show complete healing of the wound and small fistula was noticed in two teats. In treatment group, the wounds healed completely without any complications in all the animals (Figure 5). The observations on morphological examination during the postoperative period indicated the efficiency of the teat protectants made up of collagen and calcium alginate in promoting early healing of the surgical site without any appreciable complications. Calcium alginate has been proved to favor the skin ulcer healing and collagen synthesis was a critical factor for the wound closure [6]. It also aided in restoration of the healthy status of the teat and the functional capacity of the teat in all the cows in the treatment group. Jianqi *et al.* (2002) [7] Compared calcium alginate film with collagen membrane for guided bone regeneration in mandibular defects in rabbits and found calcium alginate more effective. Carvalho *et al.* (2011) [8] found that collagen calcium-alginate dressing with a transparent film covering reduces the time for complete epithelialization and may reduce pain related to skin graft donor sites. The observations on morphological examination during the postoperative period indicated the efficiency of the teat protectants made up of collagen and calcium alginate in promoting early healing of the surgical site

without any appreciable complications. It also aided in restoration of the healthy status of the teat and the functional capacity of the teat in all the cows in the treatment group.

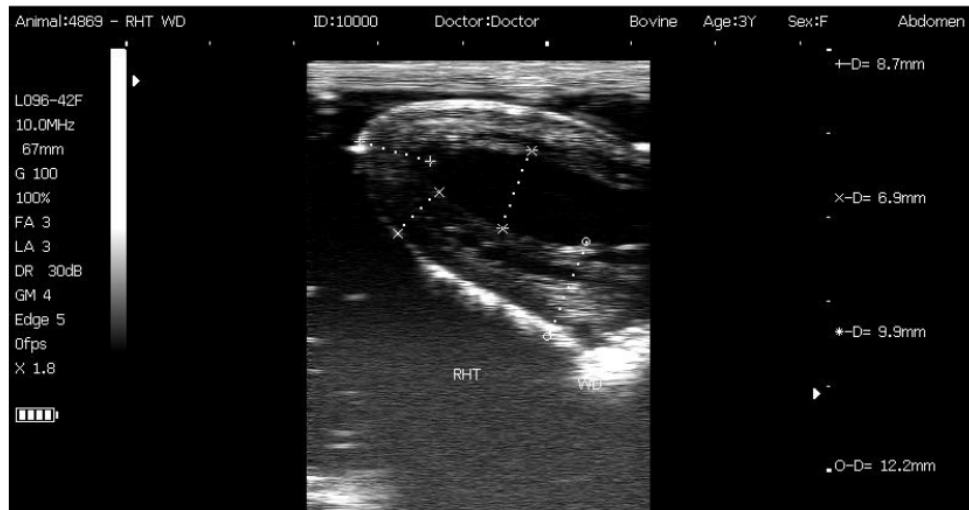

**Figure 5:** Group II: Teat showing complete wound healing on 10<sup>th</sup> day postoperatively.

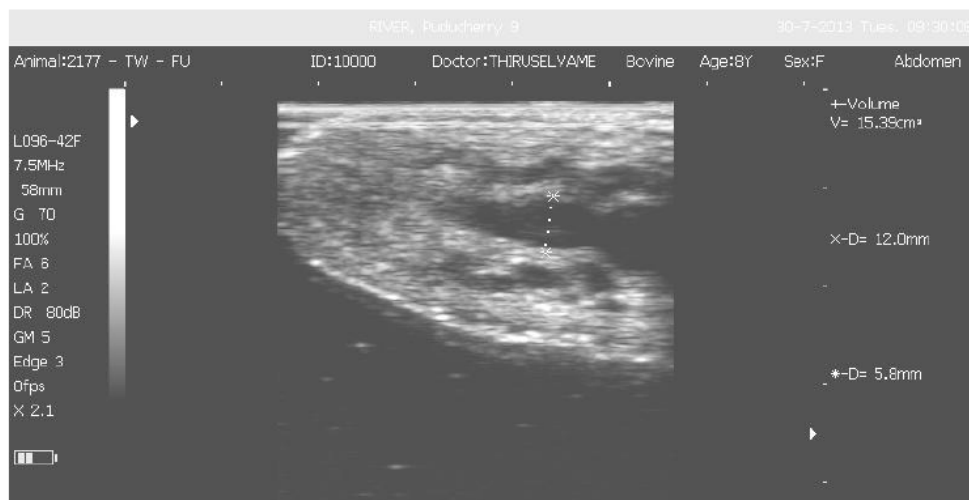On ultrasound scanning, teat with external wound and exposed teat cistern showed loss of normal echotexture of the skin on day of presentation in all the animals (Figure 6). Ultrasound scanning of the treatment group showed hyperechogenistiy of the teat wall indicating normal echotexture of the skin (Figure 7). The ultrasonographical images in the treatment group postoperatively confirmed the reduction in the size of the wound gaping approximately to an extent of 50-90% indicative of progressive healing. The ultrasonography used for the udder and teat is non-invasive method [9, 10]. Economic burden and time loss for farmers. Animal evinced pain while dressing the wound which in turn affected the milk production. The ultrasonographic images in the treatment group postoperatively confirmed the reduction in the size of the wound gaping approximately to an extent of 50-90% indicative of progressive healing.

The observations on milkability traits reflected the anatomical and functional characteristics of the affected quarter and the teat and the effectiveness of teat protectants in restoring the functional capacity of the teat due to early healing process of the wounds. The observations on milkability traits reflected the anatomical and functional characteristics of the affected quarter and the teat and the effectiveness of





**Figure 6:** Ultrasonographical image showing loss of normal echotexture of the skin of the teat on day of presentation.



**Figure 7:** Ultrasonographical image showing hyper-echoic teat wall with normal echotexture.

teat protectants in restoring the functional capacity of the teat due to early healing process of the wounds. Use of intramammary infusion containing Metronidazole and Povidone Iodine. Inj. Streptopenicillin @ 10mg/ kg body weight was effective in favouring teat wound healing.

## CONCLUSIONS

Early wound healing in teat wound is very essential to prevent mastitis in cows. Sheets of collagen and calcium alginate as protectants on the teat wound gave protection and prevented complication by hastening the healing without complications. To conclude, the application of collagen based teat protectant is an effective methodology for favoring healing process of external injuries when compared to the conventional protocols like protecting the wound with pvidone iodine gauze.

## ACKNOWLEDGEMENTS

We thank department of Science and Technology for funding this project.

## REFERENCES

- [1] Azizi S, Rezaei FS, Saifzadeh S, Dalir-Naghadeh B. Associations between teat injuries and fistula formation in lactating dairy cows treated with surgery. *J Am Vet Med Assoc* 2007; 231: 1704-1708. <https://doi.org/10.2460/javma.231.11.1704>
- [2] Nichols S. Teat laceration repair in cattle. *Vet Clin North Am Food Anim Pract* 2008; 24(2): 295-305. <https://doi.org/10.1016/j.cvfa.2008.02.016>
- [3] Nouh SR, Korittum AS, Elkammar MH, Barakat WM. Retrospective study of the surgical affections of the teat in dairy cows of the army farms and their successfully treatment. *Alexandria J Vet Sci* 2014; 40: 65-76. <https://doi.org/10.5455/ajvs.45201>
- [4] Khaled MA, Jalila A, Kalthum H, Noordin M, Asma Saleh W. Collagen-Calcium Alginate Film Dressing with Therapeutic

- Ultrasound to Treat Open Wound in Rats. Res J Biol Sci 2014; 9: 57-61.
- [5] Aruljothi N, Balagopalan TP, Rameshkumar B, Alphonse RMD. Teat fistula and its surgical management in bovines. Intas Polivet 2012; 13(1): 40-41.
- [6] Wang T, Gu Q, Zhao J, Mei J, Shao M, Pan Y, Zhang J, Wu H, Zhang Z, Liu F. Calcium alginate enhances wound healing by up-regulating the ratio of collagen types I/III in diabetic rats. Int J Clin Exp Pathol 2015; 8(6): 6636-45.
- [7] Jianqi H, Hong H, Lieping S, Genghua G. Comparison of calcium alginate film with collagen membrane for guided bone regeneration in mandibular defects in rabbits. J Oral and Maxillofacial Surg 2002; 60(12): 1449-1454. <https://doi.org/10.1053/joms.2002.36108>
- [8] Carvalho de F, Viviane, Paggiaro, Oliveira A, Isaac, Cesar; Gringlas, Júlio; Ferreira, Castro M. Clinical Trial Comparing 3 Different Wound Dressings for the Management of Partial-Thickness Skin Graft Donor Sites. J Wound Ostomy & Continence Nurs 2011; 38(6): 643-647. <https://doi.org/10.1097/WON.0b013e3182349d2f>
- [9] Porcionato MAF; Negrão JA; Lima MLP. Produção de leite, leite residual e concentração hormonal de vacas Gir × Holandesa e Holandesa em ordenha mecanizada exclusiva. Arquivo Brasileiro de Medicina Veterinária e Zootecnia 2005; 57: 820-824. <https://doi.org/10.1590/S0102-09352005000600018>
- [10] Neijenhuis F, Klungel GH, Hogeveen H. Recovery of cow teats after milking as determined by ultrasonographic scanning. J Dairy Sci 2001; 84: 2599-2606. [https://doi.org/10.3168/jds.S0022-0302\(01\)74714-5](https://doi.org/10.3168/jds.S0022-0302(01)74714-5)

---

Received on 24-02-2018

Accepted on 09-05-2018

Published on 21-05-2018

DOI: <http://dx.doi.org/10.12970/2310-0796.2018.06.01>

© 2018 Jothi and Balagopalan; Licensee Synergy Publishers.

This is an open access article licensed under the terms of the Creative Commons Attribution Non-Commercial License (<http://creativecommons.org/licenses/by-nc/3.0/>) which permits unrestricted, non-commercial use, distribution and reproduction in any medium, provided the work is properly cited.