

Auditory Neuropathy Findings Following Microvascular Decompression Surgery for Trigeminal Nerve Neuralgia: A Case Report

Naresh Durisala^{1,*} and Yeo Seng Beng²

¹*Department of Otolaryngology, Audiology clinic, Tan Tock Seng Hospital, Singapore-308433*

²*Department of Otolaryngology, Ear Nose Throat Clinic, Tan Tock Seng Hospital, Singapore-308433*

Abstract: Microvascular decompression is an established surgical remedy in people suffering from trigeminal neuralgia. Hearing loss secondary to decompression surgeries have been reported in the literature but auditory neuropathy type was rare. Here we present an unusual report of a 35 year old female patient who manifested auditory neuropathy type hearing loss following microvascular decompression for trigeminal neuralgia in the right side. Pure tone audiometry revealed a low frequency hearing loss that returned to normal. Brainstem auditory evoked responses and acoustic reflexes were absent and otoacoustic emissions were present. This case study highlights that auditory neuropathy can also be one of the possible auditory morbidities due to microvascular decompression surgery and emphasizes the importance of intra-operative auditory brainstem monitoring.

Keywords: Auditory Neuropathy, Microvascular decompression, Trigeminal neuralgia, Brainstem auditory evoked responses, Otoacoustic emissions.

INTRODUCTION

Microvascular decompression (MVD) surgery is a well established surgical procedure to relieve the compression of arteries or veins that cause trigeminal nerve neuralgia. Although the success rate of surgery was 73% to 86% [1-4] the incidence of postoperative hearing loss was found to be in the range of 0 to 23% [2, 5-7]. The types of post operative auditory morbidities include middle ear infections [8] sensorineural hearing loss [9] and retro cochlear pathology [10, 11]. One study showed a total deafness following two weeks after surgery [12] whereas another study showed a similar result after three weeks with gradual improvement over 18 month period [13]. We present here about an unusual result of a patient who manifested absent brainstem auditory evoked responses with intact outer hair cell functioning following MVD surgery for trigeminal neuralgia in the right side.

CASE REPORT

A 35 year old female with a long standing severe to profound hearing loss in the left ear presented to the Otolaryngology clinic with a complaint of difficulty in hearing in the right ear immediately after undergoing MVD surgery for trigeminal neuralgia on the same side (operated on 04/04/12). Preoperative magnetic

resonance imaging (MRI) of the brain with T1 contrast showed superior cerebellar artery impinging upon trigeminal nerve at the root entry zone with all other results being unremarkable. By using a sub-occipital approach, the neurosurgeon laterally retracted the cerebellum to access the trigeminal nerve and offending blood vessel. Neither pre nor peri-operative brainstem auditory evoked response testing was employed. There was a history of undertaking pure tone audiometric test for long standing hearing loss in the left ear but those reports were unavailable. In this case study, post-surgical audiological results pertaining only to right ear were presented.

Pure tone audiometry performed on the following day of surgery (05/04/12) revealed low frequency hearing loss (Figure 1). Following this, prednisolone was recommended at a dosage of 60mg/ day for one week and three other pure audiometry tests were performed in a span of one month. Her latest audiogram done on 28 May, 2012 revealed reversal of hearing thresholds to normal levels (Figure 2). Patient was then further followed up on 06 September, 2012 for bone anchored hearing aid (BAHA) evaluation in the left ear due to long standing hearing loss but the subjective complaints of difficulty in hearing in the right ear persisted. Pure tone audiometric thresholds were noted to be stable but speech audiometric test results showed elevated speech recognition thresholds (45 dB HL) and poor speech discrimination scores (65%) which were disproportionate with normal pure tone audiometric thresholds. Tympanometric results showed bilateral 'A' type tympanograms with absent ipsilateral

*Address correspondence to this author at the Department of Otolaryngology, Audiology Clinic, Tan Tock Seng Hospital, Singapore-308433; Tel: +65-92794911; E-mail: nareshd15@gmail.com

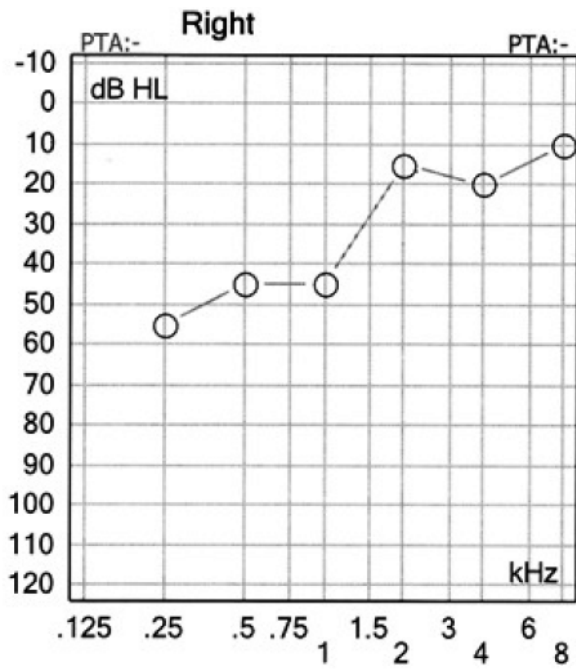


Figure 1: Pure tone hearing thresholds in the right ear following the day of surgery for trigeminal neuralgia.

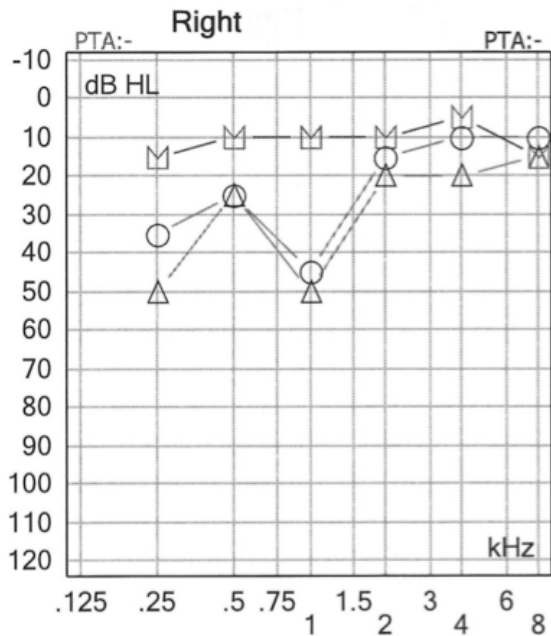


Figure 2: Three serial pure tone hearing thresholds done on different dates within a span of one month. Note: Hearing thresholds returned to normal on the top curve.

and contra lateral reflexes except at 500 Hz in the right ear (operated side). Brainstem auditory evoked response testing done on 14th September, 2012 showed absent neural responses in the right ear (operated side) at 70 dB nHL for condensation and rarefaction click stimuli presented at 11.1 pulses per second despite having normal pure tone hearing

thresholds (Figure 3). Conversely, distortion and transient otoacoustic emissions showed robust responses with over 70% reproducibility (Figure 4).

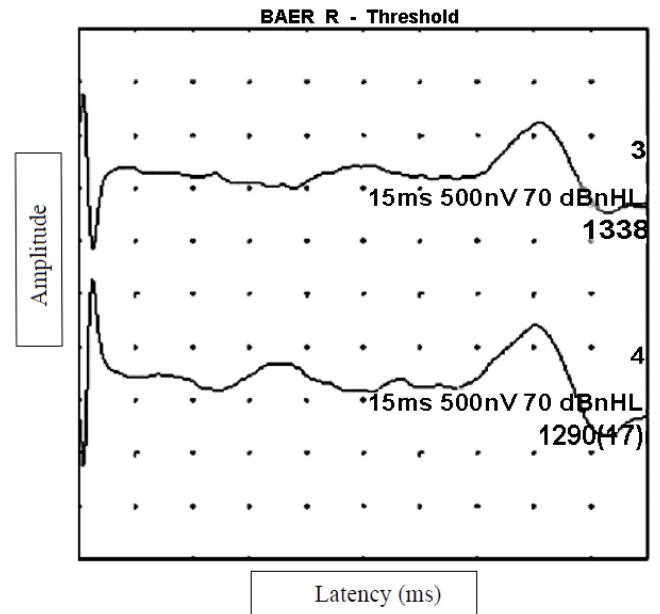


Figure 3: Absent brainstem auditory evoked responses (BAER) for condensation (top) and rarefaction (bottom) stimulus presented at 70 dBnHL. Each dot on the picture corresponds to one millisecond.

DISCUSSION

After eliminating other causative factors such as focal lesion or blood clot through post operative MRI, our patient was diagnosed with hearing loss secondary to auditory neuropathy in the right ear. This diagnosis was corroborated by cardinal test results i.e., presence of otoacoustic emissions, absent brainstem auditory evoked response and acoustic reflexes. The causes of adult onset auditory neuropathy can include infections, trauma, or hormonal changes [14] but our patient did not present with any significant history of morbidity prior to surgery, albeit with a long standing hearing loss in the left ear. Although pre-operative audiological results were unavailable to delineate the exact cause in our case, it is plausible to assume that auditory neuropathy had resulted following the surgery as the patient subjectively did not present with any hearing complaints nor had any difficulty in understanding speech in the right ear pre-operatively.

We attribute the cause to be iatrogenic where the traction of cerebellum during surgical process might have stretched the auditory nerve causing demyelination or axonal loss of the nerve fibres. Retraction of the cerebellum in lateral direction as in our case can put the auditory nerve on greater stress

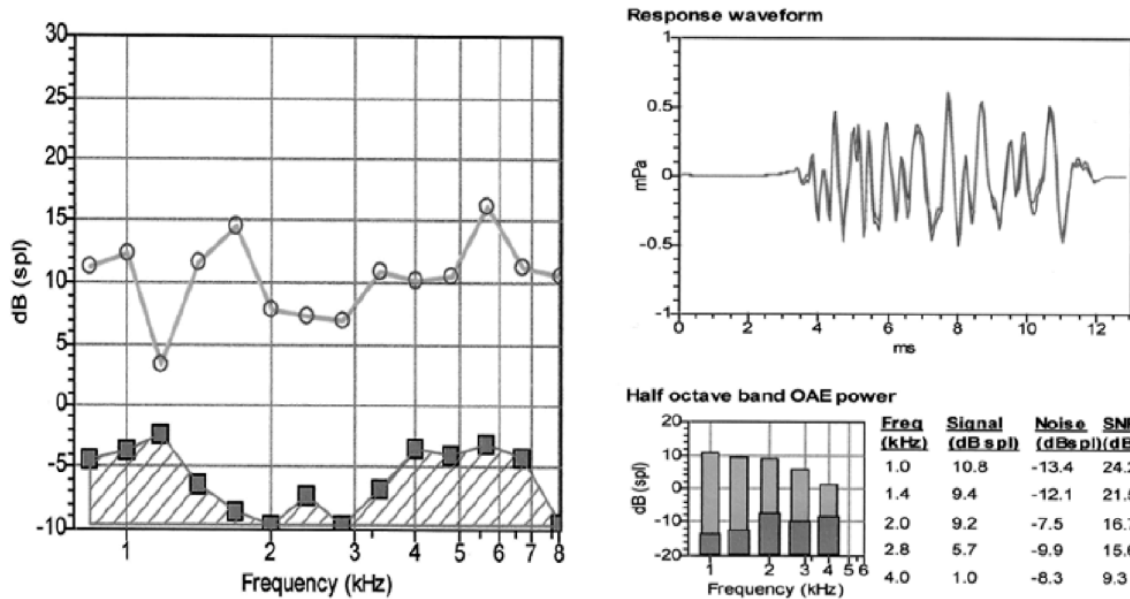


Figure 4: Left side: Normal distortion product Otoacoustic emissions (circles). Filled square boxes indicate ambient noise floor. Right Side: Normal Transient evoked Otoacoustic emissions (light bars). Darker bars indicate ambient noise floor.

compared to infero-lateral retraction [2]. Apparently this might have resulted in temporary elevation of low frequency hearing thresholds that were resolved after few days and leaving the cochlear structures intact. The presence of otoacoustic emissions and absent brainstem auditory evoked response clearly explains that hearing loss is neural in origin. The return of low frequency hearing thresholds to normal level suggests that there was recovery of neural function but the synchronous firing of neural fibres was lost. Another surprising element was the absence of wave I which is usually generated from the distal portion of the auditory nerve. This could be due to the exertion of pressure on central auditory structures that might have been transpired to the peripheral portion of the auditory nerve during surgical manipulations. The underlying pathophysiological mechanisms for absent brainstem auditory evoked response in our case may be due to dyssynchrony in the auditory nerve fibres or reduced neural input that mimics physiological mechanisms related to auditory neuropathy. As the patient did not turn up, follow up tests could not be done to document if the changes in these neural responses were permanent or temporary.

Unlike in our case study, most of the previous studies that documented changes in brainstem auditory evoked responses also documented elevation in hearing thresholds post operatively [9, 15, 16] with some improvements over month's period [14]. However one case study revealed auditory neuropathy spectrum disorder findings as in ours following a second surgery

for cerebellar astrocytoma [17]. Their study reported significant co-morbidities such as cerebellar ataxia, left-hand side abducens paresis and right-hand side peripheral facial paresis along with permanent hearing loss, absent brainstem auditory evoked responses and present otoacoustic emissions. Interestingly, one study showed a complete absence of all waves during intra-operative monitoring that were attributed to cochlear nerve compression but was resolved after cerebello-pontine angle re-exploration and correcting the offending blood vessels. The authors in their study explained that temporary loss of waves 1 and 2 was due to vascular compression on the ipsilateral side [18]. Another study [19] showed prolonged waves, 52% reduction in speech comprehension scores without any significant changes in pure tone thresholds due to vascular compression of the cochlear nerve. Nevertheless, brainstem auditory evoked responses and speech comprehension returned to normal levels in 30 days. Therefore the vascular compression as a cause for temporary elevation of low frequency hearing thresholds cannot be excluded in our case.

Incorporation of intra-operative brainstem auditory evoked response testing can reduce the risk of hearing loss [2]. It offers the clinician to assess the changes in brainstem auditory evoked responses in real time and alert the surgeon to take corrective measures. Our case study adds a new causative factor for auditory neuropathy in the literature database and highlights the importance of intra-operative brainstem auditory evoked response monitoring.

ACKNOWLEDGEMENTS

The authors would like to thank Dr. Monica Wilkinson, Dr. Vinaya Manchaiah, Dr. Jeevendra Kanagalingam, Dr. Stephen Lo and Dr. Sushmit for their helpful comments in the earlier version of the manuscript.

CONFLICT OF INTEREST

The authors report no conflict of interest. The authors alone are responsible for the content and writings of the paper.

APPENDIX

MVD = Microvascular decompression

MRI = Magnetic Resonance Imaging

BAHA = Bone Anchored Hearing Aid

REFERENCES

- [1] Sindou M, Leston J, Decullier E, Chapuis F. Microvascular decompression for primary trigeminal neuralgia: long-term effectiveness and prognostic factors in a series of 362 consecutive patients with clear-cut neurovascular conflicts who underwent pure decompression. *Journal of Neurosurgery* 2007; 107: 1144-53. <http://dx.doi.org/10.3171/JNS-07/12/1144>
- [2] Bond AE, Zada G, Gonzalez AA, Hansen C, Giannotta S.L. Operative strategies for minimizing hearing loss and other major complications associated with microvascular decompression for trigeminal neuralgia. *Journal of World Neurosurgery* 2010; 74: 172-77. <http://dx.doi.org/10.1016/j.wneu.2010.05.001>
- [3] Oesman C, Mooij JA. Long term follow up of microvascular decompression for trigeminal neuralgia. *Skull Base* 2011; 21: 313-22. <http://dx.doi.org/10.1055/s-0031-1284213>
- [4] Sekula RF, Frederickson A.M, Jannetta PJ, et al. Microvascular decompression for elderly patients with trigeminal neuralgia: A prospective study and systematic review with meta-analysis. *Journal of Neurosurgery* 2011; 114: 172-79. <http://dx.doi.org/10.3171/2010.6.JNS10142>
- [5] Barker FG, Jannetta PJ, Bionette DJ, Larkins MV, Jho HD. The long-term outcome of microvascular decompression for trigeminal neuralgia. *New England Journal of Medicine* 1996; 334: 1077-83. <http://dx.doi.org/10.1056/NEJM199604253341701>
- [6] Linskey ME, Jho MD, Jannetta PJ. Microvascular decompression for trigeminal neuralgia caused by vertebrobasilar compression. *Journal of Neurosurgery* 1994; 81: 1-9. <http://dx.doi.org/10.3171/jns.1994.81.1.0001>
- [7] Rizvi SS, Goyal RN, Calder HB. Hearing preservation in microvascular decompression for trigeminal neuralgia. *Laryngoscope* 1999; 109: 591-94. <http://dx.doi.org/10.1097/00005537-199904000-00013>
- [8] Fritz W, Schafer J, Klein H. Hearing loss after microvascular decompression for trigeminal neuralgia. *Journal of Neurosurgery* 1988; 69: 367-70. <http://dx.doi.org/10.3171/jns.1988.69.3.0367>
- [9] Ramachandran R, Mackenzie I. Brainstem auditory evoked responses during microvascular decompression for trigeminal neuralgia: Predicting post operative hearing loss. *Neurology India* 2006; 54: 250-54. <http://dx.doi.org/10.4103/0028-3886.27146>
- [10] Strauss C, Naraghi R, Bischoff B, Huk WJ, Romstock J. Contralateral hearing loss as an effect of venous congestion at the ipsilateral inferior colliculi after microvascular decompression: Report of a case. *Journal of Neurology Neurosurgery & Psychiatry* 2000; 69: 679-82. <http://dx.doi.org/10.1136/innp.69.5.679>
- [11] Vulcan AW, Ferch RD, Teddy PJ. Transient global brainstem dysfunction after microvascular decompression of the trigeminal neuralgia. *British Journal of Neurosurgery* 2004; 18: 275-77. <http://dx.doi.org/10.1080/02688690410001732733>
- [12] Kuchta J, Moller AR, Wedekind C, Jannetta PJ. Delayed hearing loss after microvascular decompression for trigeminal neuralgia. *Acta Neurochirurgica* 1998; 140: 94-97. <http://dx.doi.org/10.1007/s007010050064>
- [13] McDonnell DE, Jabbari B, Spinella G, Mueller HG, Klara PM. Delayed hearing loss after neurovascular decompression. *Neurosurgery* 1990; 27: 997-1003. <http://dx.doi.org/10.1227/00006123-199012000-00024>
- [14] Archana, Muhammad, A, Maya, Jyoti. Can hormonal influence be a cause of auditory neuropathy. *International Journal of Scientific Research* 2012; 1: 77-78.
- [15] Moller AR, Moller MB. Does intraoperative monitoring of auditory evoked potentials reduce incidence of hearing loss as a complication of microvascular decompression of cranial nerves? *Neurosurgery* 1989; 24: 254-63.
- [16] Friedman WA, Kaplan BJ, Gravenstein D, Rhoton AL. Intraoperative brainstem auditory evoked potentials during posterior fossa microvascular decompression. *Journal of Neurosurgery* 1985; 62:552-57. <http://dx.doi.org/10.3171/jns.1985.62.4.0552>
- [17] Oeken J, König E, Trantakis C, Bootz F. Unilateral deafness with persistent otoacoustic emissions after neurosurgical removal of a cerebellar astrocytoma. *Otolaryngology Head & Neck Surgery* 2001; 124: 234-235. <http://dx.doi.org/10.1067/mhn.2001.112306>
- [18] Wahlig JB, Kaufmann MA, Balzer J, Lovely TJ, Jannetta P. Intraoperative monitoring of auditory function relieved by microvascular decompression of the cochlear nerve. *The Canadian Journal of Neurological Sciences* 1999; 26: 44-47.
- [19] Raudzens PA. Intraoperative monitoring of evoked potentials. *Annals of New York Academy Sciences* 1982; 308-326. <http://dx.doi.org/10.1111/j.1749-6632.1982.tb50799.x>

Received on 25-11-2013

Accepted on 29-11-2013

Published on 30-11-2013

DOI: <http://dx.doi.org/10.12970/2311-1917.2013.01.01.1>

© 2013 Durisala and Beng; Licensee Synergy Publishers.

This is an open access article licensed under the terms of the Creative Commons Attribution Non-Commercial License (<http://creativecommons.org/licenses/by-nc/3.0/>) which permits unrestricted, non-commercial use, distribution and reproduction in any medium, provided the work is properly cited.