

# Successful Treatment to Dermatitis Papillaris Capilliti (Kaposi) with Kampo (Japanese Traditional Herbal Medicine) Formulations

Ichiro Kurokawa<sup>1,\*</sup>, Tomoko Konishi<sup>1,2</sup>, Ayako Kakuno<sup>2</sup> and Masaru Natsuaki<sup>3</sup>

<sup>1</sup>Department of Dermatology, Acne Clinical Research Center, Meiwa Hospital, Japan

<sup>2</sup>Department of Pathology, Meiwa Hospital, Japan

<sup>3</sup>Department of Dermatology, Hyogo College of Medicine, Japan

**Abstract:** We report a case of dermatitis papillaris capilliti (DPC) that was successfully treated with Kampo (Japanese traditional herbal medicine) formulations (Keigai-rengyo-to and Keishi-bukuryo-gan). A 38-year-old man presented with longstanding-therapy resistant papillomatous lesions on the occipital area and nape for 15 years. Diagnosis was made as DPC. He had also cystic acne. Histopathological findings revealed follicular hyperkeratosis in the infundibulum and fibrosis in the dermis. After Kampo formulations (Keigai-rengyo-to and Keishi-bukuryo-gan) were administered, inflamed and granulomatous lesions subsided remarkably. The successful treatment with these herbal formulations shows Kampo therapy can act as an alternative treatment for DPC.

**Keywords:** Dermatitis papillaris capilliti, Kampo, Keigai-rengyo-to, Keishi-bukuryo-gan.

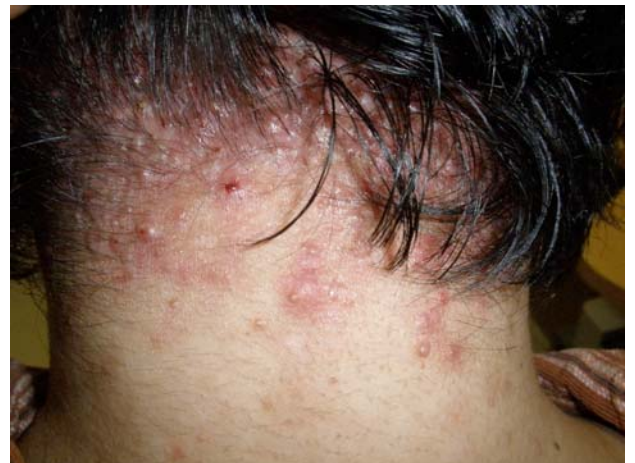## INTRODUCTION

Dermatitis papillaris capilliti (DPC) belongs to one of the follicular occlusion diseases. It is also known as acne keloidalis and folliculitis nuchae [1]. The etiology of DPC is unclear. It is a refractory therapy resistant disease. DPC occurs preferentially in middle age. Treatment for DPC is extremely difficult. It has been treated with oral and topical antimicrobials, traniLAST, intralesional steroid injection, and surgical therapy [1]. These treatments are not always satisfactory for patients. We report a case of DPC treated successfully with Kampo formulations (Keigai-rengyo-to and Keishi-bukuryo-gan).

## CASE REPORT

A 38-year-old man presented with recurrent therapy-resistant purulent lesions on the nape and occipital area for 15 years. His case history showed papillary exudative hemorrhagic nodules and cysts on the occipital area and nape for those 15 years. The lesions manifested red deep-seated follicular aggregated nodules, granulomatous nodules, erosion, hypertrophic scar and keloids, and tufted hairs with clear exudate discharge and hemorrhage (Figure 1). He also had cystic nodules on the face (acne cystica). He had been treated for 15 years with antimicrobials such as oral minocyclines, cephalosporins and topical antimicrobials (clindamycin and nadifloxacin). The lesions did not respond to these therapies. A skin

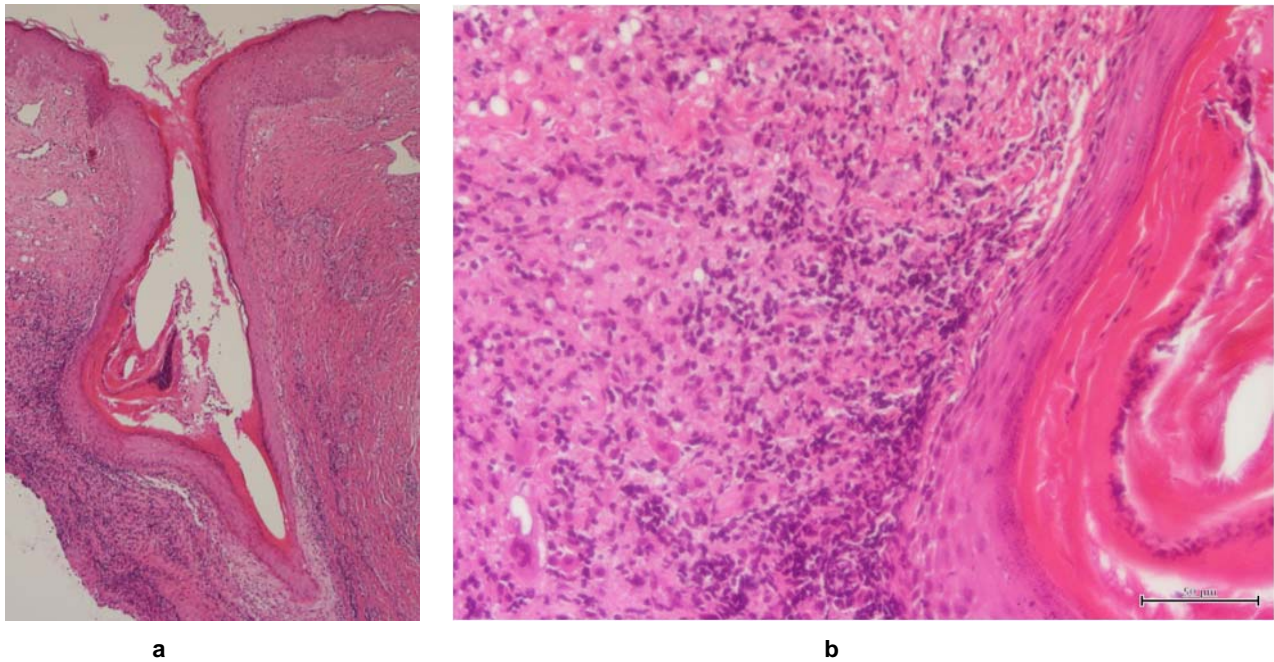
biopsy was performed. H&E staining showed obstruction of follicle with remarkable hyperkeratosis in the follicular infundibulum, and perifollicular cell infiltration in the upper dermis (Figure 2a). Higher magnification showed hyperkeratosis with keratohyaline granules and dense neutrophils, lymphocytes and plasma cells and fibrosis around the follicle in the dermis (Figure 2b). Bacterial culture from the lesions found *Staphylococcus epidermidis*. Laboratory findings showed elevated WBC (13660/ $\mu$ l), ALT (77 U/dl), ZTT (31.8 IU/dl), CRP(0.81 mg/dl), and IgM(226 mg/dl). Serum cortisol, testosterone, and free testosterone were within normal limits.



**Figure 1:** Red deep-seated follicular aggregated nodules, granulomatous nodules, erosion, hypertrophic scar, keloids, and tufted hairs with clear exudate discharge and hemorrhage on the occipital area.

Based on clinical and histopathological findings, we diagnosed as DPC. The patient was treated with oral and topical antimicrobials. However, the lesions did not

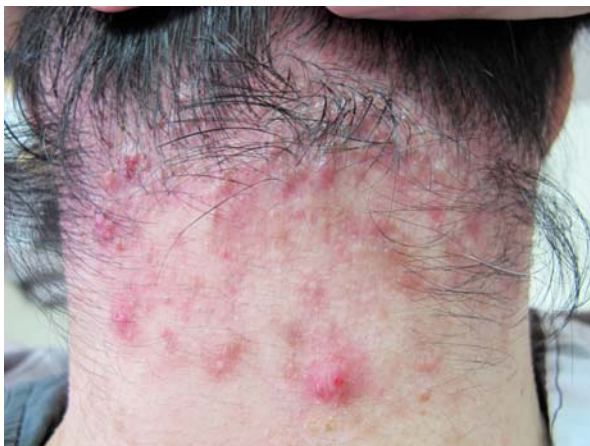\*Address correspondence to this author at the Department of Dermatology, Acne Clinical Research Center, Meiwa Hospital, Japan; Tel: +81-798-47-1767; Fax: +81-798-47-7613; E-mail: kurokawa.i@meiwa-hospital.com



**Figure 2:** **a:** Histopathological findings showed obstruction of follicle with remarkable hyperkeratosis in the follicular infundibulum, and perifollicular cell infiltration in the upper dermis (Figure 2a). **b:** Higher magnification showed hyperkeratosis with keratohyaline granules and dense neutrophils, lymphocytes and plasma cells and fibrosis around the follicle in the dermis (Figure 2b).

respond to these treatments. Then, we decided to administer Kampo treatment (Japanese traditional herbal therapy: Keigai-rengyo-to and Keishi-bukuryo-gan).

After two weeks, the inflamed and granulomatous lesions had subsided remarkably (Figure 3). The therapy lasted for 6 months and his skin lesions almost healed up.



**Figure 3:** The inflamed and granulomatous lesions had subsided remarkably.

## DISCUSSION

DPC represents deep chronic folliculitis, and occurs in men rather than women. The preferential area is

nape and occipital area. DPC occurs more in men having a fat neck. The etiology of DPC is unclear. The anatomical site, bacterial infection, and autoimmune response may be involved. Abnormal keratin expression has been reported recently [2]. Clinically, aggregated recurrent pustules are prominent. Histopathology shows that the infundibulum and isthmus in hair follicle are destroyed [3]. The hairs are spilled out in the dermis. However, the sebaceous gland is absent [3]. DPC is categorized as one of follicular occlusion diseases.

It is also referred to as acne keloidalis. DPC is very resistant to therapy. In our case, oral and topical antimicrobials therapy was administered. However, these therapies were not effective. Then we decided to administer Japanese herbal treatment.

Because there has been reported successful treatment for chronic pyoderma of the scalp with Kampo formulations (Keigai-rengyo-to and Keishi-bukuryo-gan) [4]. The status of DPC are considered to be stagnation of the local circulation, hemorrhage and chronic inflammation. The skin color is dark with exudative bleeding. Keishi-Bukuryo-gan improves peripheral circulation, and the elimination of pathogens and waste products [5]. Keigai-rengyo-to (KG) exerts anti-inflammatory and anti-toxic effects. It is effective for acne vulgaris due to its anti-bacterial effects [6].

In KG, one of medial plant, *Phellodeni Cortex*, has very strong antimicrobial activity against *Propionibacterium acnes* [6] with berberine [7]. KG is also effective for granulomatous diseases such as sarcoidosis [7]. It can suppress active oxygen due to decreased neutrophil-generated O<sub>2</sub><sup>-</sup>, H<sub>2</sub>O<sub>2</sub> and OH, resulting in anti-inflammatory effect on acne lesions [8]. The pathophysiological mechanism by which these Japanese herbs affect on the pathogenesis of DPC is unclear. Nevertheless, these drugs can function as an alternative adjuvant therapy for DPC.

Further cases with DPC should be studied to elucidate the pathomechanism involved.

## REFERENCES

- [1] Acne Keloidalis Nuchae. Acne & Rosacea. In edited by Plewig G & Kligman AM, Springer-Verlag 2000; pp. 332-3.
- [2] Kurokawa I, Konishi T, Kakuno A, Tsubura A. Keratin and filaggrin expression in dermatitis papillaris capilliti. Int J Dermatol (in press).
- [3] Dinehart SM, Herzberg AJ, Kerns BJ, Pollack SV. Acne keloidalis. A review. J Dermatol Surg Oncol 1989; 15(6): 642-7.
- [4] Natsuaki M. Application of Keigai-rengyo-to to therapy-resistant cutaneous diseases. Current status due to Kampo therapy in dermatology. Sogoigaku-sha, Tokyo 1996; pp. 25-34 (in Japanese).
- [5] Disturbance of ki, ketsu, and sui. Introduction to Kampo. Japanese Traditional Medicine. In edited by The Japanese Society for Oriental Medicine (Sato Y, *et al.*), Elsevier, Tokyo 2005; pp. 47-52.
- [6] Higaki S, Nakamura M, Morohashi M, Yamagishi T. *Propionibacterium acnes* biotypes and susceptibility to minocycline and Keigai-rengyo-to. Int J Dermatol 2004; 43(2): 103-7.
- [7] Hirano A, Natsuaki M, Miyata A, Yamanishi K. A successful treatment on cutaneous lesions of sarcoidosis with Keigai-rengyo-to. Skin Res 2005; 4(4): 366-9.
- [8] Akamatsu H, Asada Y, Horio T. Effect of keigai-rengyo-to, a Japanese kampo medicine, on neutrophil functions: a possible mechanism of action of keigai-rengyo-to in acne. J Int Med Res 1997; 25(5): 255-65.

Received on 05-09-2013

Accepted on 31-10-2013

Published on 30-11-2013

DOI: <http://dx.doi.org/10.12970/2310-998X.2013.01.01.5>

© 2013 Kurokawa *et al.*; Licensee Synergy Publishers.

This is an open access article licensed under the terms of the Creative Commons Attribution Non-Commercial License (<http://creativecommons.org/licenses/by-nc/3.0/>) which permits unrestricted, non-commercial use, distribution and reproduction in any medium, provided the work is properly cited.